

# Barrett's Oesophagus

Parul Dureja

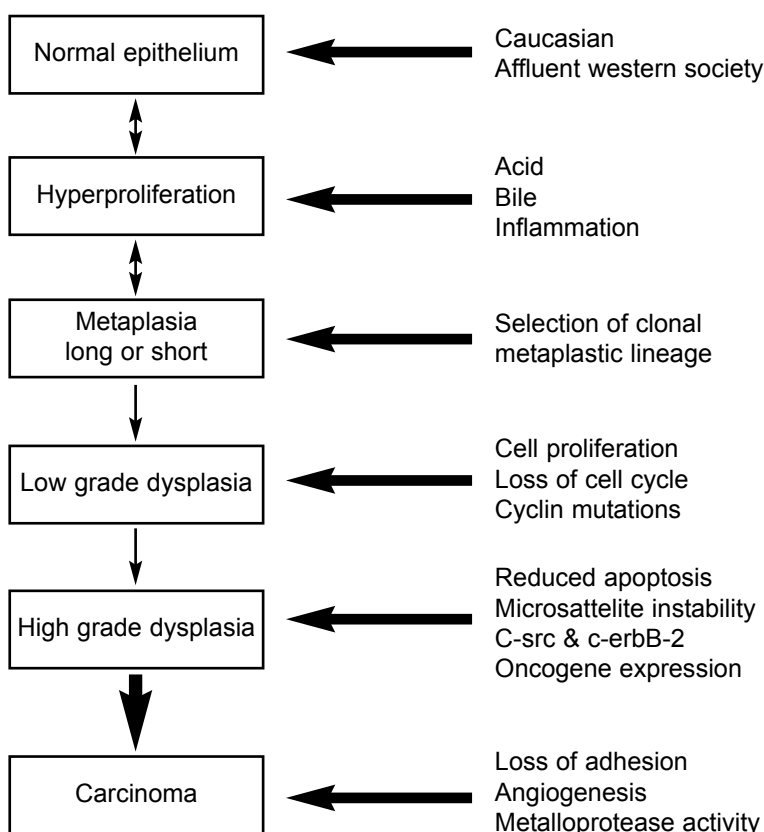
Oesophageal adenocarcinoma has increased in incidence by more than 70% in the last 20 years, and its incidence is increasing more rapidly than that of any other malignancy in the Western world.<sup>1,2</sup> Despite advances in multimodal therapy, the prognosis for invasive oesophageal adenocarcinoma is poor. Barrett's oesophagus is the most significant risk factor for the development of oesophageal adenocarcinoma. The annual risk of oesophageal adenocarcinoma for patients with Barrett's metaplasia is approximately 1%, a figure 30-40 times that of the general population.<sup>1</sup> The management of Barrett's oesophagus is controversial, and it is not yet known whether surveillance for detection of early invasive adenocarcinomas improves survival. An improved understanding of the molecular biology of this disease may allow improved diagnosis, therapy, and prognosis.

## DEVELOPMENT OF BARRETT'S OESOPHAGUS

Barrett's oesophagus is defined as the replacement of the distal oesophageal squamous epithelium by specialized intestinal epithelium, characterized by the presence of

goblet cells.<sup>1</sup> There is considerable evidence that Barrett's oesophagus is an acquired condition, which occurs as a complication of long-standing gastro-oesophageal reflux of acid and particularly bile. Approximately 10% of patients with chronic gastro-oesophageal reflux disease (GORD) will develop Barrett's oesophagus.<sup>2</sup>

Barrett's epithelium and its malignant transformation occur in a stepwise process from metaplasia through dysplasia to invasive adenocarcinoma, and involve a wide variety of cellular and molecular changes (Figure 1).<sup>1</sup> The process by which specialized intestinal epithelium replaces squamous epithelium is poorly understood. One proposed theory is that longstanding GORD produces inflammation and eventually ulceration of the squamous epithelial lining.<sup>3</sup> The response to cell death and inflammation includes increased folding of the oesophageal epithelium, which results in stem cells becoming more superficial.<sup>1</sup> In the microenvironment of an abnormally low pH in the distal oesophagus, these superficial stem cells may become damaged or die, or they may differentiate into an abnormal columnar epithelium that is thought to be more resistant to injury from refluxing gastric contents.<sup>3</sup>



**Figure 1.** Schematic representation of the proposed metaplasia-dysplasia-carcinoma sequence for the evolution of Barrett's oesophagus and oesophageal carcinoma (reproduced from Aldulaimi et al, *Dis Esophagus* 1999; 12(3):177-80).

## MANAGEMENT

The American College of Gastroenterology recommends regular endoscopic surveillance of patients with Barrett's oesophagus.<sup>4</sup> However, surveillance with multiple biopsies is costly and inconvenient, and it remains controversial whether it reduces mortality. The aim is to detect high-grade dysplasia as it is the precursor lesion to adenocarcinoma. The rationale of endoscopic surveillance is to offer oesophagectomy, assuming the patient is fit, either before the development of adenocarcinoma or at an early stage. A selective surveillance policy, aimed at only those at greatest risk, would increase the cost-effectiveness and reduce the endoscopic burden.<sup>2</sup>

There is currently considerable controversy regarding the appropriate management of patients with Barrett's oesophagus. The aim of treatment is more to influence the natural progression of the disease rather than symptom relief, as many patients are asymptomatic owing to reduced mucosal sensitivity.<sup>2</sup> Two studies have shown a lesser influence of acid suppression therapy on the natural course of the disease when compared with antireflux surgery.<sup>2,5</sup> This is attributed to the fact that treatment with high dose proton pump inhibitors (PPI) normalizes oesophageal acid exposure, but is relatively ineffective in reducing bile reflux compared to fundoplication.

Several other factors suggest that surgical management of Barrett's oesophagus may be preferable to long term acid suppression therapy. First, in contrast to acid suppression therapy alone, antireflux surgery corrects underlying defects that are often present in patients with Barrett's oesophagus, such as lower oesophageal sphincter tone, hiatus hernia, and duodenogastro-oesophageal reflux. In addition, successful antireflux surgery offers complete and continuous reflux control. This is especially important as *in vitro* studies show that intermittent acid exposure causes greater cell proliferation and de-differentiation of Barrett's oesophageal cells than both continuous or no acid exposure.<sup>2</sup> This finding has also been observed *in vivo*; a study from the Karolinska Institute suggested that acid suppression therapy increases threefold the odds ratio of patients with GORD developing adenocarcinoma.<sup>6</sup> Two studies also show a lower incidence of dysplasia and adenocarcinoma among patients treated with fundoplication versus those treated with acid suppression therapy alone.<sup>7,8</sup>

In recent years, endoscopic ablative techniques have been proposed as techniques to reverse Barrett's oesophagus.<sup>9</sup> A number of

techniques (in combination with acid suppression) are being investigated and these include photodynamic therapy (PDT), laser photocoagulation, argon plasma coagulation (APC), electrocoagulation, heater probe, and cryotherapy. The side effect profile of these procedures and confirmation of their potential to produce long-term risk reduction of adenocarcinoma have yet to be elucidated.

## CELLULAR AND MOLECULAR CHANGES

An improved understanding has been gained of the polyp-carcinoma sequence in the colon in recent years. Much research is presently being carried out into the metaplasia-dysplasia-carcinoma sequence of the oesophagus, but the precise mechanisms are still poorly understood. Various cellular and molecular changes are involved in the malignant transformation of Barrett's epithelium (Figure 1). These include mutations in the p53 tumour suppressor gene, and alterations in the statement of various oncogenes, such as c-src, c-erbB-2, and c-myc.<sup>1</sup> Recent evidence also suggests a role for abnormalities in cellular adhesion molecules in the development of invasive oesophageal adenocarcinoma. Alterations in the statement of various adhesion molecules are thought to result in a reduction in cellular adhesion, allowing invasion and metastases.<sup>1</sup>

Investigators are currently examining the potential role pro-inflammatory cytokines, namely tumour necrosis factor-alpha (TNF- $\alpha$ ) and interleukin-1 (IL-1), play in the progression of Barrett's epithelium to adenocarcinoma. It is thought that TNF- $\alpha$  and IL-1 released in response to chronic GORD may mediate their effect through activation of the NF- $\kappa$ B pathway. NF- $\kappa$ B comprises a family of inducible transcription factors that serve as important regulators of the host immune and inflammatory response.<sup>10</sup> The NF- $\kappa$ B pathway is a key mediator of genes involved of cellular proliferation and apoptosis. TNF- $\alpha$  and IL-1 released in response to chronic GORD may activate the NF- $\kappa$ B pathway, thereby inducing the statement of anti-apoptotic genes and establishing a positive feedback loop for their statement. The statement of anti-apoptotic genes may then impair apoptosis and potentiate the effects of increased proliferation of stem cells in Barrett's epithelium.

## CONCLUSION

The appropriate management of patients with Barrett's oesophagus remains a subject of great debate. Barrett's oesophagus and its progression to oesophageal adenocarcinoma is associated with a wide variety of mol-

ecular and cellular changes which parallel histological progression from metaplasia through dysplasia to invasive cancer. An improved understanding of these molecular changes may

help to target those in need of regular surveillance and could lead to improved treatment in the future.

---

## REFERENCES

1. Aldulaimi D, Jankowski J. Barrett's oesophagus: an overview of the molecular biology. *Dis Esophagus* 1999; 12(3):177-80.
2. Watson A. Barrett's oesophagus – 50 years on. *Br J Surg* 2000; 87(5):529-31.
3. Kumar V, Cotran RS. Basic Pathology, W.B. Saunders Company, 6th ed (USA). 1997.
4. Sampliner, RE. Practice guidelines on the diagnosis, surveillance, and therapy of Barrett's oesophagus. The Practice Parameters Committee of the American College of Gastroenterology. *Am J Gastroenterol* 1998; 93(7):1028-31.
5. Attwood SE, Barlow AP, Norris TK, et al. Barrett's oesophagus: effect of anti-reflux surgery on symptom control and development of complications. *Br J Surg* 1992; 79(10):1050-3.
6. Lagergren J, Bergstrom R, Lindgren A, et al. Symptomatic gastroesophageal reflux as a risk factor for esophageal adenocarcinoma. *N Engl J Med* 1999; 340(11):825-31.
7. McDonald ML, Trastek VF, Allen MS, et al. Barrett's esophagus: does an antireflux procedure reduce the need for endoscopic surveillance? *J Thorac Cardiovasc Surg* 1996; 111(6):1135-40.
8. Stein HJ, Kauer WK, Feussner H. Bile reflux in benign and malignant Barrett's oesophagus: effect of medical acid suppression and Nissen fundoplication. *J Gastrointest Surg* 1998; 2(4):333-41.
9. Sharma P. An update on strategies for eradication for Barrett's mucosa. *Am J Med* 2001; 111(8a):147S-52S.
10. Yamamoto Y, Gaynor RB. Therapeutic potential of inhibition of the NF-kappaB pathway in the treatment of inflammation and cancer. *J Clin Invest* 2001; 107(2):135-41.