

Why is Retreatment Less Successful than Conventional Root Canal Treatment?

Padhraig Fleming

INTRODUCTION

Endodontic therapy is one of the most progressive aspects of modern dentistry. Significant advancements in debridement and obturation techniques have occurred in recent years. Consequently, success rates approaching 90% have been reported.¹ However, endodontic procedures can be among the most technically challenging faced by many dentists. Root fillings can, and do fail and failures necessitate retreatment. Likewise, asymptomatic root fillings occasionally require retreatment prior to elaborate prosthodontic procedures, as endodontic failure may follow expensive restorative work. Success rates for conventional endodontic treatment are often reported at 80-85%.²⁻⁴ Factors dictating success or failure include⁵ the presence of pre-operative periapical radiolucency,⁴ the apical extent of filling,³ the quality of obturation, the observation period,² any iatrogenic complications and post-endodontic restoration.⁶

Follow-up studies on endodontically retreated teeth having pre-operative rarefactions report markedly lower success rates of 47-77%.^{4,7-8} Interestingly, however, teeth retreated for technical or restorative reasons enjoy very high success rates of 93.8-98%, illustrating the importance of pre-operative periapical status in governing endodontic success or otherwise.^{4,7-8}

WHY DO ROOT CANAL FILLINGS FAIL?

Intra-radicular Bacteria

These are considered causative in over 80% of cases. Micro-organisms colonizing root canals play a vital role in the pathogenesis of periradicular lesions. Sundqvist first proved this role in vivo.¹⁰ He discovered that bacteria were only detected in root canals of pulpless teeth with periapical bone destruction. Causes of residual intra-radicular bacteria include incomplete debridement, coronal leakage and missed canals.¹¹

Extra-radicular Bacteria

Some bacterial species are capable of survival outside the root canal in the periradicular tissues thereby inducing peri-apical

pathology. *Actinomyces* species and *Propionibacterium propinicum* may be implicated in extra-radicular infection.^{12,13} Bacterial organisation into biofilms may also permit their evasion of host defences.

True Cysts

Ramachandran Nair used sectioning techniques to examine peri-apical lesions. He deduced that 15% of these lesions were, in fact, cysts. He further sub-divided cysts into "true" or "bay." Bay cysts communicate with the root canal. However, true cysts do not. Thus, they are refractory to even technically excellent conventional or orthograde retreatment approaches. Surgical retreatment is necessitated in this situation. This theory is not accepted universally, however.

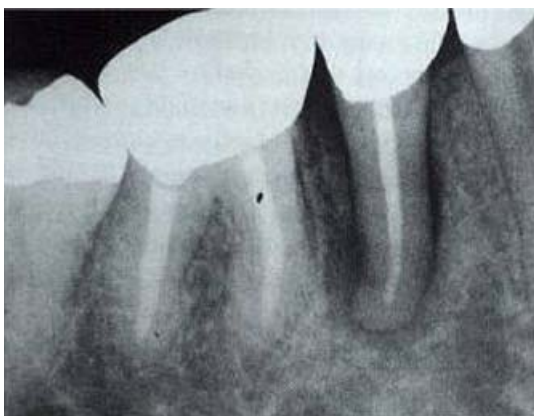
Extra-radicular Foreign Materials

Rarely, endodontic procedures may fail because of intrinsic or extrinsic non-microbial factors. Foreign body reactions against cholesterol crystals derived from disintegrating host cells have been implicated in failure.¹⁴ Extrinsic factors include talc in gutta-percha cones, cellulose components of paper points and cotton wool if extruded into the peri-apical tissues.^{15,16} Leaving a tooth in open drainage is also ill advised. Complications arising from these teeth are often very difficult to treat.

Undiagnosed Vertical Root Fracture

Such teeth are often misdiagnosed as endodontic failures. The prevention of unnecessary and inevitable endodontic failure in these retreatment cases resides in careful history-taking, examination and diagnosis. The use of diagnostic aids, such as microscopes, radiographs (Figure 1), periodontal probing, tooth slooth, dyes, transillumination and, occasionally, surgical exposure, is crucial in these cases. According to Chong and Pitt-Ford, the basic difference between root canal retreatment and initial root canal treatment is the need to remove the previous root filling before a tooth can be retreated.¹⁷ This suggestion may be over-simplistic as removal of old restorations is one of a number of different challenges

Figure 1. Example of a radiograph. Note the radiolucent "halo" surrounding mandibular second premolar suggestive of a root fracture.



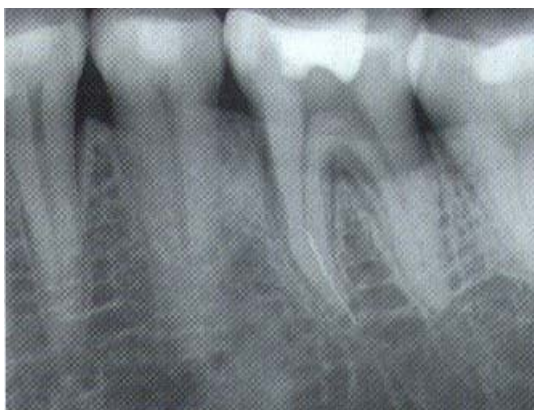encountered in retreatment cases (e.g. different microflora, negotiation of procedural errors and overcoming aberrant anatomy).

GAINING ACCESS

Occasionally posts must be removed from teeth having insufficient coronal tooth structure to support a workable coronal restoration for endodontic or prosthodontic reasons. Post removal may be achieved by, ultrasound, post-removing devices (e.g. Post puller, Gonon post removal system), masserann instrument (this is associated with a 55% success rate, is less successful in posterior teeth and is very time-consuming.¹⁹), or drilling with a bur.¹⁷ These procedures are often quite technically demanding, cumbersome and are associated with significant morbidity.

Other materials sometimes requiring removal include silver points, gutta percha, thermafil, paste and cement, and broken instruments (Fig. 2). Silver points tend to be extremely difficult and time-consuming to remove as are broken instruments.²⁰ Some cements for example SPAD, which sets harder

Figure 2. Broken instrument in apical one third of mesial root of a mandibular first molar.



than dentine, and AH26 are particularly difficult and often impossible to remove. Removal is thus fraught with danger and surgery may be a more sensible option in selected cases.

However, with careful case-selection and thorough mechanical and chemical debridement, stainless steel files may often be left in situ without greatly affecting the prognosis.^{21,22}

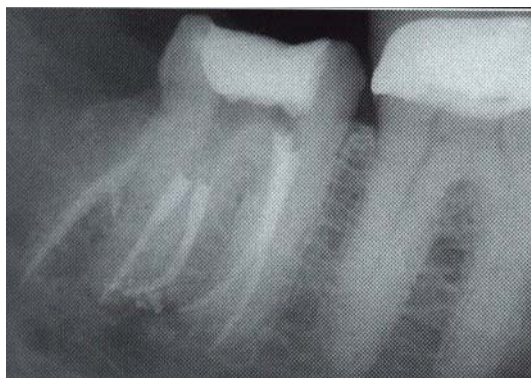
These procedures must be performed with great care as a number of undesirable complications may occur including root fracture, file fracture, the removal of excess root dentine predisposing to future fracture, canal perforation, and extrusion of objects beyond root apex.²³

Without due care and attention catastrophic failures may ensue. I believe many of these early failures are not included in the clinical studies documenting success rates for retreatment procedures.^{4,7,8}

ANATOMIC VARIATION

Missed canals are a common cause of root canal treatment failure as they often harbour bacteria and related irritants contributing to clinical symptoms. Aberrant or unusual anatomy must be considered in retreatment cases. Because the success rates of endodontic procedures are now so high we must expect unusual anatomy or some other mitigating factor as contributory particularly if the obturation appears satisfactory radiographically i.e. dense, 3D obturation of the canal system to within 1mm of the radiographic apex. Several roots have additional canals (Fig. 3).²⁴ For example: maxillary first molars which often (78% of cases approximately) contain 2 canals in the mesio-buccal root²⁵; maxillary first premolars which are occasionally three-rooted. Each root contains a separate canal²⁶; mandibular incisors which contain two canals in over 40% of cases²⁷; and mandibular first molars which contain four canals in approx.

Figure 3. Five canals in a mandibular second molar.



one third of cases.²⁸

Anatomic familiarity is essential before re-entering a root canal-treated tooth. Other aids in detection include radiographic analysis (Canals are generally "centered" in the root. Therefore, deviation from the mid-root is often an indication of the presence of a second system.), digital radiographs, magnification (An operating microscope with supplementary illumination facilitates the localization of "missed" canals and the removal of canal obstructions²⁹), expanded access cavities (Isthmus areas should be probed with explorers in an effort to detect a "catch" suggestive of another orifice.), ultrasonics, micro-openers, dyes (for example methylene blue, which may be used to "roadmap" anatomy), and sodium hypochlorite. The clinician must be aware of root canal complexities. They must expect the unexpected where root canal morphology is concerned. This approach is particularly warranted in retreatment cases.

THE MICROBIOLOGY OF ROOT CANAL THERAPY FAILURE

The microbiology of root canals exhibiting failing endodontic therapy is markedly different from that of an untreated canal.^{30,31} The latter is often a mixed infection, in which gram-negative anaerobic rods predominate. The former is usually composed of 1-2 species, generally gram-positive bacteria. In particular levels of *Enterococcus faecalis* are raised. In Sundqvist's study³¹ 38% of failing canals harboured the bacterium. Increased proportions of *E. faecalis* in teeth lacking adequate seal during treatment or treated over more than ten visits have been reported³² supporting the suggestion that *E. faecalis* enters the canal during treatment. *E. faecalis* strains have shown resistance to intra-canal medicaments for example calcium hydroxide.³³ Therefore this bacterium commonly appears in refractory cases, usually as the single species of microorganism present. Consequently, endodontic retreatment is very prone to failure in these specific cases. Yeast-like microorganisms have also been isolated from failing root fillings.³⁴ Like *E. faecalis* some *Candida* species are resistant to commonly deployed intra-canal medicaments. Therefore, the microflora of failing endodontic fillings may be extremely resistant and difficult to eradicate thereby predisposing to infection and thus, failure of retreatment. Modified and more potent intracanal medicaments may be required to enhance the elimination of resistant bacteria in these retreated canals.

OVERCOMING PROCEDURAL ERRORS

Procedural errors performed during the initial root canal treatment of an infected tooth may predispose to failure. Procedural accidents often impede or render it impossible to accomplish effective intra-canal procedures.³⁵ These iatrogenic factors must often be overcome to effect successful retreatment, which is obviously more demanding than conventional root treatment.

Blocked canals are often encountered in retreatment cases. Attempts to get to working length and allow thorough cleaning of the whole root canal system are painstaking. These procedures require perseverance and patience. Copious full-strength (5.25%) sodium hypochlorite irrigant may be used in combination with pre-curved, narrow files used in an apically directed picking motion to loosen the material. Viscous chelators may also be used to work the file to length. This procedure is often very difficult and fails. In such instances, regardless of the quality of obturation, the patient must be informed of the likelihood of endodontic failure (particularly if the previous filling failed clinically). Consequently, inadequate initial mechanical debridement may reduce the prognosis of initial root treatment and decrease the likelihood of successful retreatment if necessitated.

Ledges represent an internal transportation of the canal. They may be bypassed using the same techniques as used for "blocks".³⁶ Ledges may be reduced or removed using Greater Taper Ni-Ti files. However, clinicians must be wary of removing excess dentine in an attempt to completely remove the ledge.

Another problem often encountered in retreatment cases is apical transportation. Canals exhibiting apical transportation tend to be internally underfilled. Mild transportations may be dealt with by simple cleaning, shaping and obturation. Again, however, extra root dentine may be sacrificed predisposing to subsequent root fracture. Moderate transportation may be negotiated using mineral trioxide aggregate (MTA).³⁷ Severe transportation, however, carries an almost hopeless prognosis if using conventional retreatment means. Hence, retrograde means are needed to ensure success. In this instance case selection is vital in ensuring success of endodontic retreatment, which has been affected adversely by careless initial treatment.

Root perforation is a procedural error that can have a profound effect on the prognosis of treatment.³⁸ Perforations are a common cause of endodontic failure.³⁹ Hence, they are

regularly encountered in retreatment cases. It has been claimed that non-surgical treatment of perforation is limited because of the difficulty in determining the perforation's location, shape and size in addition to the lack of matrix against which the sealing material can be packed without excess spreading to the periradicular tissues.⁴⁰ Materials used in perforation repair include calcium hydroxide, amalgam, intermediate restorative material, composite resin and gutta percha. The use of biocompatible matrices e.g. tricalcium phosphate or hydroxyapatite, have been proposed in order to control the extrusion of repair material.⁴¹ More recently MTA has been deployed in perforation repair. It has been claimed that MTA affords a biocompatible immediate seal to the perforation site with optimum healing.⁴² Undoubtedly, however, despite this recent advance perforations do represent a mitigating factor likely to affect adversely success rates of endodontic retreatments.⁴³

SURGICAL ENDODONTIC RETREATMENT

Surgical retreatment carries a considerably lower success rate than conventional retreatment.⁴ Guttman and Harrison report success rates of 25-90%.⁴⁴ However, endodontic surgery is specifically indicated in the following situations: failed orthograde treatment where access to the canal is impossible conventionally; obstructed canals in a symptomatic tooth; apical perforations failing to respond to repair material for example MTA; grossly over-extended filling material in a symptomatic tooth; and horizontal fracture at the apex in a symptomatic tooth.

In the above cases conventional retreatment should be carried out if possible to eliminate bacteria and related irritants from the root canal system. This approach prevents the likelihood of placement of a "lid on a sewer".⁴⁵ Zuolo, Ferreira and Guttman⁴⁶ reported success rates of 91.2% overall for surgical treatment preceded by orthograde retreatment. The importance of conservative retreatment was shown in another study where there was a 24% higher retreatment success rate in cases of failed endodontic therapy in which antibacterial measures and refilling of the canal preceded apical surgery, than in cases in which apical surgery was the only treatment performed, was reported.⁴⁷

CONCLUSION

Overall, retreatment is less successful than primary root canal treatment. Retreatment procedures are complicated by difficulties in accessing canals to allow effective cleaning and shaping of the system, overcoming procedural errors, aberrant anatomy and an increasingly resistant microflora. Candidates for retreatment are likely to be very "dentally aware" as they have already had initial root treatment. Consequently, patient education and case presentation are vital. Patients should be informed that retreatment carries a poorer prognosis (particularly if symptomatic at the outset) and complications may arise necessitating surgery or removal of the tooth. Clinicians must consider specialist referral in particularly difficult cases. However, careful case selection, examination, trouble-shooting and endodontic work can guarantee success even in complicated retreatment cases.

REFERENCES

1. Smith CS, Setchell DJ, Harty FJ. Factors influencing the success of conventional root canal therapy--a five-year retrospective study. *Int Endod J* 1993; 26(6):321-33.
2. Strindberg LZ. The dependence of the results of pulp therapy on certain factors: An analytical study based on radiographic and clinical follow-up examinations. *Acta Odont Scand* 1956; 14(suppl 21):1-175.
3. Seltzer S, Bender IB, Turkenkopf S. Factors affecting successful repair after root canal therapy. *J Am Dent Assoc* 1963; 67:651-62.
4. Sjogren U, Hagglund B, Sundqvist G, et al. Factors affecting the long-term results of endodontic treatment. *J Endod* 1993; 16(10):498-504.
5. Cheung GS. Endodontic failures – changing the approach. *Int Dent J* 1996; 46:131-8.
6. Ray HA, Trope M. Periapical status of endodontically treated teeth in relation to the technical quality of the root filling and the coronal restoration. *Int Endod J* 1995; 28(1):12-8.
7. Bergenholtz G, Lekholm U, Milthorpe R, et al. Retreatment of endodontic fillings. *Scand J Dent Res* 1979; 87(3):217-24.
8. Allen RK, Newton CW, Brown CE. A statistical analysis of surgical and non-surgical retreatment cases. *J Endod* 1989; 15:261-6.
9. O' Driscoll P. Endodontics – a report. *J Ir Dent Assoc* 1996; 46:72-3.
10. Sundqvist G. Associations between microbial species in dental root canal infections. *Oral Microbiol Immunol* 1992; 7:257-62.
11. Saunders WP, Saunders EM. Coronal leakage as a cause of failure in root-canal therapy: a review. *Endod Dent Traumatol* 1994; 10(3):105-8.
12. Sundqvist G, Reuterberg CO. Isolation of

- Actinomyces israelii from periapical lesion. *J Endod* 1980; 6(6):602-6.
13. Sjogren U, Happonen RP, Kahnberg KE, et al . Survival of Arachnia propionica in periapical tissue. *Int Endod J* 1988; 21(4):277-82.
 14. Nair R, Sjogren U, Sundqvist G. Cholesterol crystals as an etiological factor in non-resolving chronic inflammation: an experimental study in guinea pigs. *Eur J Oral Sci* 1998; 106(2 Pt 1):644-50.
 15. Nair PN, Sjogren U, Krey G, et al. Therapy-resistant foreign body giant cell granuloma at the periapex of a root-filled human tooth. *J Endod* 1990; 16(12):589-95.
 16. Koppang HS, Koppang R, Solheim T, et al. Cellulose fibers from endodontic paper points as an etiological factor in postendodontic periapical granulomas and cysts. *J Endod* 1989; 15(8):369-72.
 17. Chong BS, Pitt Ford TR. Endodontic retreatment. 2: Methods. *Dent Update* 1996; 23(9):384-7, 390.
 18. Sorenson JA, Martinoff JT. Intracoronal reinforcement and coronal coverage: a study of endodontically treated teeth. *J Prosthet Dent* 1984; 51(6):780-4.
 19. Williams VD, Bjorndahl AM. The Masserann technique for the removal of fractured posts in endodontically treated teeth. *J Prosthet Dent* 1983; 49:46-8.
 20. Fors UGH, Berg JO. Endodontic treatment of root canals obstructed by foreign objects. *Int Endod J* 1986; 19(1):2-10.
 21. Crump MC, Natkin E. Relationship of broken root canal instruments to endodontic case prognosis: a clinical investigation. *J Am Dent Assoc* 1970; 80(6):1341-7.
 22. Fox J, Moodnik RN, Greenfeld E, et al. Filling root canals with files: radiographic evaluation of 304 cases. *NY State Dent J* 1972; 38:154-7.
 23. Nagai O, Yahji N, Kayaba Y, et al. Ultrasonic removal of broken instruments in root canals. *Int Endo J* 1986; 19:298-304.
 24. Burns RC, Herbranson EJ. Tooth morphology and cavity preparations. Cohen S, Burns RC, eds. Pathways of the pulp, ed 7. St Louis 1998, Mosby.
 25. Al Shalabi RM, Omer OE, Glennon J, et al. Root canal anatomy of maxillary first and second permanent molars. *Int Endod J* 2000; 33(5):405-14.
 26. Kartal N, Ozcelik O, Cimilli H. Root canal morphology of maxillary premolars. *J Endod* 1998; 24(6):417-9.
 27. Benjamin KA, Dowson J. Incidence of two root canals in human mandibular incisor teeth. *Oral Surg Oral Med Oral Pathol* 1974; 38(1):122-6.
 28. Skidmore AE, Bjorndal AM. Root canal morphology of the human mandibular first molar. *Oral Surg Oral Med Oral Pathol* 1971; 32(5):778-84.
 29. Carr GB. Microscopes in Endodontics. *J Calif Dent Assoc* 1992; 20:55-61.
 30. Molander A, Reit C, Dahlen G, et al. Microbiological status of root-filled teeth with apical periodontitis. *Int Endod J* 1998; 31(1):1-7.
 31. Sundqvist G, Figdor D, Persson S, et al. Microbiologic analysis of teeth with failed endodontic treatment and the outcome of conservative re-treatment. *Oral Surg Oral Med Oral Pathol Oral Radiol Endod* 1998; 85(1):86-93.
 32. Siren EK, Haapsalo MPP, Ranta K, et al. Microbiological findings and clinical treatment procedures in endodontic cases selected for microbiological investigation. *Int Endod J* 1997; 30(2):91-5.
 33. Bystrom A, Sundqvist G. The antibacterial action of sodium hypochlorite and EDTA in 60 cases of endodontic therapy. *Int Endod J* 1985; 18(1):35-40.
 34. Nair PNR, Sjogren U, Kahnberg KE, et al. Intraradicular bacteria and fungi in root-filled, asymptomatic human teeth with therapy-resistant periapical lesions: a long-term light and electron microscopic follow-up study. *J Endod* 1990; 16(12):580-8.
 35. Sequeira JF. Aetiology of root canal treatment failure: why well-treated teeth can fail. *Int Endo J* 2001; 34:1-10.
 36. Ruddle CJ. Nonsurgical endodontic retreatment. *J Calif Dent Assoc* 1997; 25(11): 769-75, 777, 779-86 passim.
 37. Lee SJ, Monsef M, Torabinejad M. Sealing ability of a mineral trioxide aggregate for repair of lateral root perforations. *J Endod* 1993; 19(11):541-4.
 38. Firas Daoudi M. Microscopic management of endodontic procedural errors: perforation repair. *Dent Update* 2001; 28(4):176-80.
 39. Ingle J. A standardised endodontic technique utilising newly designed instruments and filling technique. *Oral Surg Oral Med Oral Pathol* 1961; 14:83-91.
 40. Lantz B, Persson PA. Periodontal tissue reactions after surgical treatment of root perforations in dogs' teeth. A histologic study. *Odontol Rev* 1970; 21(1):51-62.
 41. Alhadainy HA. Root perforations. A review of literature. *Oral Surg Oral Med Oral Pathol* 1994; 78(3):368-74.
 42. Nakata TT, Bae KS, Baumgartner JC. Perforation repair comparing mineral trioxide aggregate and amalgam using an anaerobic bacterial leakage model. *J Endod* 1998; 24(3):184-6.
 43. Seltzer S, Bender IB, Smith J, Freedman I, Nazimov H. Endodontic failures--an analysis based on clinical, roentgenographic, and histologic findings. 1 & 2. *Oral Surg Oral Med Oral Pathol* 1967; 23(4):500-30.
 44. Guttman JL, Harrison JW. Surgical Endodontics. Blackwell Scientific Publications. Boston MA, USA.
 45. Rud J, Andreason JO. A study of failures after endodontic surgery by radiographic, histologic and stereomicroscopic methods. *Int J of Oral Surg* 1972, 311-28.
 46. Zuolo ML, Ferreira MO, Gutmann JL. Prognosis in periradicular surgery: a clinical perspective. *Int Endo J* 2000; 33:91-8.
 47. Grung B, Molven O, Halse A. Periapical surgery in a Norwegian county hospital: follow-up findings of 477 teeth. *J Endod* 1990; 16:411-7.