

# A New Method to Quantify Mitral Regurgitation

Sandeep Bhachu

## INTRODUCTION

In cases of mitral regurgitation, the severity of the regurgitation is the major determinant of progression to left ventricular dilatation and dysfunction. Therefore, precise measurement of regurgitant volume in patients with mitral regurgitation is important for evaluating the progression of the disease which can then determine the optimal time for surgical repair or replacement.<sup>1</sup> A wide range of analytic approaches and diagnostic technologies have been proposed to aid clinical evaluation of mitral regurgitation. Yet all existing quantification methods have shown limitations in one form or another. The aim of this paper is to present a new technique based on a control volume method which can accurately quantify mitral regurgitation with the use of velocity encoded magnetic resonance images.

## MITRAL REGURGITATION

Mitral valve regurgitation, also known as mitral insufficiency, is a disorder in which the mitral heart valve does not close properly, causing blood to regurgitate into the left atrium when the left ventricle contracts. As a result, the left ventricle has to pump more blood to make up for the leakage and thus gradually enlarges to increase the force of each heartbeat. The left atrium also tends to enlarge to accommodate the extra blood being pushed back from the ventricle.<sup>2</sup> However, profound enlargement of the atrium often results in atrial fibrillation, triggering the ventricles to contract more rapidly and reducing the heart's pumping efficiency. The lack of proper blood flow through the ventricle allows blood clots to form which, if dislodged, will be pumped out of the heart and may block a smaller artery possibly causing a stroke or other damage. Finally, severe regurgitation reduces the forward flow of blood sufficiently to cause heart failure and death.<sup>3</sup>

Although medication may temporarily decrease symptoms, the only proven treatment for mitral regurgitation is surgical repair or replacement of the valve. There have been significant advances in the way mitral valve surgery is performed, and in otherwise relatively healthy patients, the risks for major complications including death are relatively low, in the order of 3-5%.<sup>4</sup> Even though surgical correction is highly successful, the operative risk in valve repair or replacement, despite recent improvements, is still far from negligible. Therefore surgery,

particularly for patients with minimal or no symptoms, should be considered only for patients with well-documented severe mitral regurgitation.<sup>1</sup> Consequently, determining the degree of regurgitation is a crucial part of the clinical evaluation of patients with mitral regurgitation.

Throughout the past decade, there has been a great deal of research into the quantification of mitral regurgitation to determine the level of severity of the disease.<sup>5</sup> A wide range of analytic approaches and quantification techniques have been proposed to aid clinical evaluation and decision-making. However, mitral regurgitation currently has no gold standard against which to determine the regurgitant volume.<sup>6</sup> Thus, the optimal management of patients with the disease is still controversial. The two most commonly used quantification techniques to date are left ventriculography and cardiac catheterisation, and colour doppler echocardiography. Each approach has limitations and inaccuracies. For instance, left ventriculography and cardiac catheterisation is invasive, time-consuming and is not feasible for repeated measurements since it has inherent risks. In addition, in order to calculate the heart's ejection fraction it utilizes assumptions concerning the properties of the left ventricle that may not be true.<sup>7,8</sup>

Colour doppler echocardiography can determine and display the direction and velocity of blood flow in the heart chambers and vessels and subsequently produce an image of the regurgitant jet. Although this technique allows one to establish the presence of mitral regurgitation, the quantification is imprecise.<sup>8</sup> Essentially, the technique attempts to solve a three-dimensional problem from a two-dimensional image by measuring the jet area.<sup>9</sup> A correlation does exist between size and volume flow. However, it is not perfect and thus masks the true volume of blood flow back through the mitral valve.<sup>10</sup>

Thus, the quantification of mitral regurgitation continues to remain an important but elusive clinical goal. With today's technological advances, the goal of improving and developing new techniques is within our grasp. Ideally, an accurate, rapid, non-invasive and widely available technique for quantifying mitral regurgitation is desirable. A more accurate classification of the disease severity would enable the medical

community to predict disease progression more accurately and plan more timely surgical interventions. Such a quantification technique may exist with the use of magnetic resonance imaging (MRI).<sup>11,12</sup>

**CONTROL VOLUME THEORY**

In order to study a phenomenon such as the regurgitant volume, the physical system must be isolated from its surroundings and mathematical models that describe it must be developed. It is here that we utilise the concept of a control volume.<sup>13</sup>

A control volume can be thought of as a finite region, chosen carefully by the analyst, with open boundaries through which mass, momentum, energy are allowed to cross. The analyst will then be able to determine the balance between the incoming and outgoing fluid, and the resultant changes within the control volume. The result is a powerful tool.

In a recent study, the quantification of aortic regurgitation has been shown to be possible if a single MRI phase velocity encoded slice is positioned perpendicular in the aorta close to the aortic valve.<sup>12</sup> This type of MRI image is unconventional in that its intensity is independent of signal magnitude but directly proportional to blood flow velocity.<sup>14</sup> Thus, one can measure the velocity of blood flowing forward and backward through the aortic valve. This process, which in the past has been referred to as the single slice method is appropriate for the aortic valve as the aortic flow field and anatomy are relatively simple during the period of regurgitation. Simply speaking, aortic regurgitation can be isolated by a single plane placed through the aortic sinus allowing the regurgitation flow to be calculated accurately. Once the flow rate (velocity x area) has been determined, integration of the aortic flow curve over the diastolic period can then provide the regurgitant volume per cardiac cycle.<sup>15</sup> However, this method cannot be used in the same manner for mitral regurgitation. Unfortunately, for the quantification of mitral regurgitation, the complex left ventricular flow field and anatomy make it almost impossible to place a single slice such that it isolates the regurgitant flow (figure 1). In particular, the presence of the strong left ventricular ejection flows over the anterior mitral leaflet and the width of the left ventricle prevent this.<sup>16</sup> To combat these limitations a new method had to be considered. This has led to the development of the control volume theory to quantify mitral regurgitation.

The success of this new theory depends on obtaining a number of contiguous side by side velocity encoded MRI slices centered on the

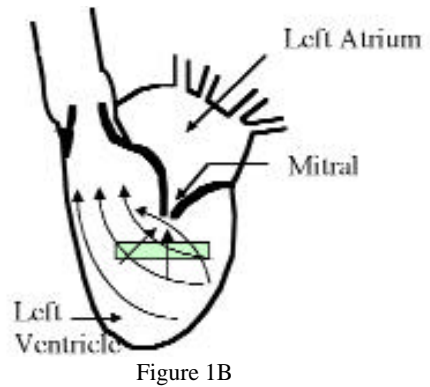
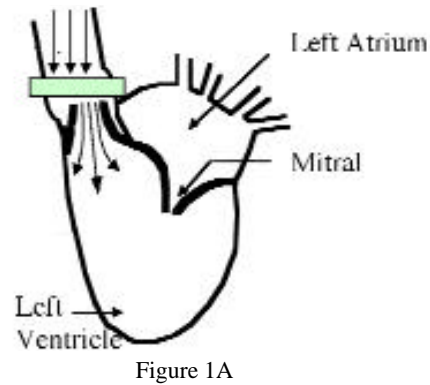


Figure 1: Single Slice Method. The single slice method can be done to quantify aortic regurgitation (Fig. 1A), however cannot be used for mitral regurgitation because of the complex flow field (Fig. 1B). As one can see, flow going through the MRI slice is not guaranteed to contribute to the regurgitant flow thus invalidating the procedure.

mitral valve regurgitant orifice. This type of MRI allows the operator to measure all three velocity components (x, y, z) of fluid passing through those slices; the velocity of blood in the right-left direction (x-axis), anterior-posterior direction (y-axis), and in the foot-head direction (z-axis). A control surface is then drawn encompassing the mitral valve (figure 2).<sup>17</sup>

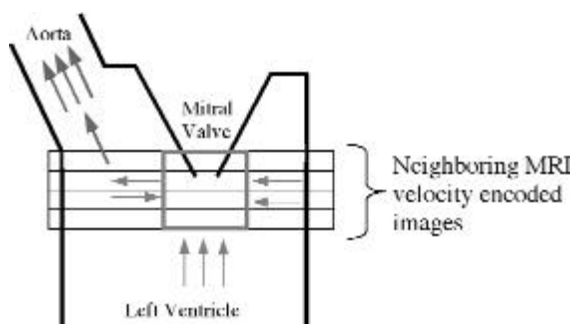


Figure 2: Blood flow (arrows) surrounding the mitral valve can be isolated by an imaginary control volume box (outlined) with the use of multiple MRI images.

Since the box will be constructed to cut the regurgitant orifice parallel to the orifice plane, there will be a ventricular side to the box and an atrial side.<sup>15</sup> Assuming fluid is incompressible and since matter cannot be created or destroyed, the principle of mass conservation states that the

inflow into this box is also equal to the outflow. Theoretically, the net volume of fluid which enters the control box during systole should be equal to the regurgitant volume given that its only exit is through the mitral valve. Furthermore, since the control surface is drawn such that it encloses only the regurgitant orifice, the ventricular outflow to the aorta will not be incorporated into the flow rate calculations.<sup>15,16</sup> The control volume method is therefore robust, appropriate and probably necessary for the quantification of mitral regurgitation.

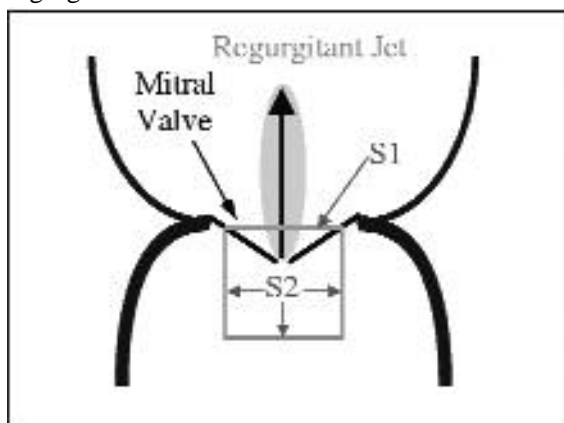


Figure 3: Diagram showing the control surface enclosing a regurgitant mitral valve. S1 = the part of the control surface on the atrial side of the mitral valve; S2 = the part of the control surface on the ventricular side of the mitral valve.

We can deduce from figure 3 that the net flow going into the ventricular side of the control box must be equal to the regurgitant flow on the atrial side (S1). With the MRI images supplying the velocity of fluid, the flow rate of fluid crossing the boundaries can be calculated by the product of the normal velocity  $\times$  area. An easier tactic may be to calculate the atrial side (S1) directly; however, because of the difficulties in obtaining accurate velocity measurements in the turbulent regurgitant jet, this approach is not possible. Therefore in order to quantify the regurgitant flow, the term S2 must be evaluated.<sup>16</sup> This area is an imaginary three-dimensional cube and in order to obtain the flow rate through one side of the cube (the side which contains the regurgitant jet), the flow rate through the other five sides must be determined. Summing the flow rate for the five sides will then give a net total flow rate, which is the negative equivalent of the flow rate going through the sixth (atrial) side. By obtaining the net flow rates going into the ventricular side of the CV box over time, the total regurgitant volume can then be determined by integration of the flow rates with respect to time over the systolic phase.<sup>16</sup>

#### WHY USE MRI?

Magnetic resonance imaging is an

attractive tool for evaluation of patients with various heart diseases. First, it is safe and easily performed in an outpatient setting without the need for intravenous injections or the use of ionizing radiation.<sup>8</sup> Second, it provides cardiovascular flow information rapidly and efficiently. Because of its ability to produce images relatively inexpensively and also non-invasively, it allows repetitive evaluations of the left ventricular and regurgitant volume measurements to be made in a safe manner. Also the ability of MRI to obtain tomographic images in virtually any plane gives it a tremendous advantage over other imaging techniques. Its capability to acquire blood flow velocity information in all three dimensions within a single slice also provides MRI with an advantage over conventional imaging techniques.<sup>18</sup> This particular feature is especially important as it is the limiting factor for the other quantifying techniques when calculating the flow rate. It is necessary that only the velocity perpendicular to the surface be integrated since the other velocity components do not pass through the control volume surface. They therefore cannot contribute to the flow out of or into the control volume.<sup>15</sup> Doppler ultrasound, for example, can be used only to measure a single velocity component and thus, it cannot be used to measure the velocity normal to each surface.<sup>12</sup> As this is needed to calculate the true flow rate, the ultrasound method will result in calculating an inaccurate flow rate. MRI is superior in this respect. The velocity is measured in each pixel of the MRI image and each velocity component is measured individually so that the vertical, horizontal, and through-plane velocities are separate images.<sup>17</sup> In order to account for cardiac motion and the pulsatility of the flow, a number of MR images are obtained per heartbeat. These are approximately 20 to 40 milliseconds apart and are synchronized with the heartbeat by triggering the acquisition of data from the patient's electrocardiography (ECG).<sup>12</sup> Lastly, by using data obtained from MRI, the need for an assumed shape for the control volume is removed. Any shaped control volume could be used because the velocity component normal to the control volume surface can always be calculated from the three separate velocity components. To simplify the calculation however, a rectangular control volume is used.

#### CONCLUSION

In the clinical decision making process regarding mitral regurgitation, accurate determination of the severity of the disease is of major importance. The risk of surgery warrants confirmation of severity by a complementary

method. At present however, mitral regurgitation has no gold standard against which to quantify the regurgitant volume.<sup>6</sup> In addition, the effects of medication to treat symptoms and underlying conditions associated with mitral valve regurgitation cannot be studied in more detail as no quantification technique today can monitor the relative changes of the regurgitation process accurately without some type of invasive procedure.<sup>5,6</sup> This paper explores a new MRI technique that could in theory accurately and safely quantify mitral regurgitation using a control volume method. The concepts behind the technique begin with taking a number of neighboring imaging slices in the vicinity of the

mitral orifice and measuring all three-dimensional velocity components via MR velocity encoded imaging. An imaginary three dimensional control volume box is then constructed to encompass the mitral valve. True to the principle of mass conservation, the calculated net inflow into the imaginary box from the ventricular side is equal to the regurgitant flow through the orifice.<sup>16</sup> No studies yet describe the testing of this technique in-vivo, however, studies from in-vitro flow phantom have shown excellent results in terms of precision.<sup>15,16</sup> With further work, this technique has the possibility of ending the search for an accurate non-invasive method to quantify mitral regurgitation.

## REFERENCES

1. Dujardin KS, Enriquez-Sarano M, Bailey KR, Nishimura RA, et al. Grading of Mitral Regurgitation by Quantitative Doppler Echocardiography. *Circulation* 1996;10:3409-3423
2. Kumar P, Clark M. Clinical Medicine. 5th Edition. London: W. B. Saunders; 2002.
3. Alpert JS, Dalen JE, Dhahbudin HR. Valvular Heart Disease. 3rd Edition. Philadelphia: Lippincott Williams & Wilkins; 2000
4. Schmidt M, Crnac J, Dederichs B, Theissen P, et al. Magnetic Resonance Imaging in Valvular Heart Disease. *Intern J of Cardiac Imaging* 1997;13:219-231
5. Wilkerson PW, Levine RA, Yoganathan AP. Quantification of Mitral Regurgitation Using Corrected Doppler Measurements. *Journal of Biomechanical Engineering* 1999 June;121:273-280
6. Thomas L, Foster E, Hoffman JI, Schiller NB. The Mitral Regurgitation Index: An Echocardiographic Guide to Severity. *J Am Coll Cardiol* 1999;33(7):2016-22
7. Fujita N, Chazouilleres AN, Hartiala JJ, O'Sullivan M, et al. Quantification of Mitral Regurgitation by Velocity-Encoded Cine Nuclear Magnetic Resonance Imaging. *J Am Coll Cardiol* 1994;23(4):951-8
8. Hundley WG, Li HF, Willard JE, Landau C, et al. Magnetic Resonance Imaging Assessment of the Severity of Mitral Regurgitation. Comparison with Invasive Techniques. *Circulation* 1995 Sept;92(5):1151-8
9. Chalki HP, Nishimura RA, Enriquez-Sarano M, Reeder GS. A Simplified, Practical Approach to Assessment of Severity of Mitral Regurgitation by Doppler Color Flow Imaging with Proximal Convergence. *Mayo Clin Proc.* 1998; 73:929-935
10. Giesler M, Crossmann G, Schmidt A, Kochs M, et al. Color Doppler Echocardiographic Determination of Mitral regurgitant Flow from the Proximal Velocity Profile of the Flow Convergence Region. *The American Journal of Cardiology* 1993;71:217-223
11. Hopmeyer J, Wilkerson PW, Thorvig KM, Levine RA, et al. Pulsatile flow Computational Simulations of Mitral Regurgitation. *Journal of Biomechanical Engineering.* 1998 April;120:245-254
12. Walker PG, Cranney GB, Scheidegger MB, Waseleski G, et al. A New Control Volume Method for Calculating Valvular Regurgitation. *Circulation* 1995;92:579-586
13. White FM. Fluid mechanics. 4th Edition. Boston London: McGraw-Hill; 1999
14. Pettigrew RI, Oshinski JN, Chatzimavroudis G, Dixon WT. MRI Techniques for Cardiovascular Imaging. *Journal of MRI* 1999;10:590-601
15. Chatzimavroudis GP, Oshinski JN, Pettigrew RI, Walker PG, Franch RH, Yoganathan AP. Quantification of Mitral Regurgitation With MR Phase Velocity Mapping Using a Control Volume Method. *Journal of MRI* 1998;8:577-582
16. Walker PG, Houlind K, Djurhuus C, Kim WY, et al. Motion Correction for the Quantification of Mitral Regurgitation Using a Control Volume Method. *Magnetic Resonance in Medicine* 2000;43:726-733
17. Globits S, Higgins CB. Assessment of Valvular Heart Disease by Magnetic Resonance Imaging. *Am Heart J.* 1995;129:369-81
18. Schmidt, M., Crnac, J, Theissen P, Schicha H, et al. Magnetic Resonance Imaging in Valvular Heart Disease. *International Journal of Cardiac Imaging* 1997;13:219-231